

HOW TO IMPROVE TUBEROSITY FIXATION IN HEMIARTHROPLASTY FOR FRACTURE?

> L. Obert, A. Adam, S Rochet, R. Sadnia, T. Lascar*

Corresponding Author:

L. Obert Orthopedic, Traumatology, Plastic and Hand Surgery Unit & CIC IT 808
University Hospital of Besançon, Besançon, France F25033

Research Unit: EA 4268 I4S IFR 133 INSERM Medical & Pharmaceutical Faculty,
University of Franche Comté

* Orthopedic and Traumatology unit, Princess Grace Hospital, Monaco

Email: obert@chu-besancon.fr

HEMIARTHROPLASTY FOR FRACTURE - YES, BUT WHY?

In a patient above 70 years of age with a non-displaced, four-part fracture, immobilization for four to six weeks remains the gold standard for treatment. If the fracture is displaced and the patient is active, seeking the best functional outcome is legitimate. But how far should this go? A recent study exposes the problem: Over 65 years of age, there is no difference a year later between a four-part fracture treated conservatively and one treated with hemiarthroplasty (1). Which fractures, patients and operating techniques are at issue here? Patients with proximal humerus fractures in these age groups have a high rate of mortality in the year following the fracture. This detail, which actually isn't one, should be considered when the therapeutic procedure is outlined to the family. Finally, we have all pursued at one time an indication of osteosynthesis in this type of fracture and in these age groups, either for reasons of caution (and quite rightly so) and for a defensive therapeutic outcome (for example, what if the prosthesis became infected?). However in this type of fracture, there are two problems (quantitative and qualitative) that can explain the high number of failures with the various types of fixation systems. In fact, screwing in a plate or using pins, whether locked or not, can fulfill the requirements of a stable, permanent fixation in two fragment fractures where the bone stock provides sufficient anchorage. But as soon as the head is separated from the tuberosities, the head is not thick enough (a quantitative problem) and the cancellous bone is not of good enough quality (a qualitative problem) to support fixation. Thus as was noted by Clavert (2) and recently echoed by Schliemann (3), the complication rate is between 20 and 40% with this type of fracture (four-part), this type of bone (porous) and this age group (over 70) when osteosynthesis is chosen. A recent study comparing osteosynthesis and hemiarthroplasty over time (three and six months) showed better results in the hemiarthroplasty group (4).

THE CHALLENGE OF HEMIARTHROPLASTY: TUBEROSITY FIXATION HOW AND WHERE TO FIX THEM?

Without a humeral head, the "ideal" anatomical position of tuberosities is not so easy to find. A pre-operative CT scan analysis is mandatory for all four-part fractures and the presence of an image intensifier in the operative field is crucial (Figure 1)

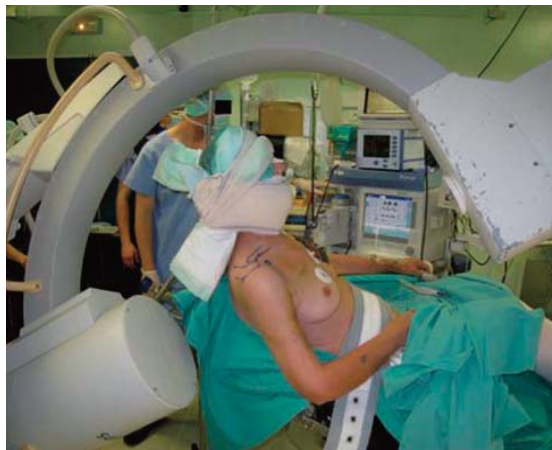

Figure 1: Fluoroscopy system and position of the patient

In our opinion, the deltopectoral approach provides a more global exposure to evaluate the best fixation position. The superior approach confers a feeling of symmetry but is less relevant for positioning the lesser tuberosity of humerus; however positioning the greater tuberosity from the front is always possible if not always easy. It will take an inexperienced surgeon some time to understand that, at the end of the surgical procedure, the prosthetic head will disappear since it will be covered with the two tuberosities that are brought back on either side of the fracture line. But everything happens around the humeral stem. When the placement of the humeral stem is good, the tuberosities are also at the correct level. Thus the height of the tuberosities directly depends on the height of the stem. The optimal position of the tuberosities is determined in the three spatial planes but their respective volume, which varies from fracture to fracture, makes it difficult to set out a technique that can be reproduced by everyone in every situation. The distance between the upper pole of the stem and the upper edge of the greater tuberosity of the humerus must be equal to 5 mm. But intraoperatively, this measurement is difficult to take because the tuberosities align themselves after the stem has been fixed. The bicipital groove and the long biceps are symmetrical markers separating both tuberosities. However, this may be deceiving when the lesser tuberosity contains a portion of the groove, since the anatomy is not consistent from one person to another. Thus, the first step consists of finding, isolating and fitting each tuberosity with sutures. Fracture landmarks such as the unevenness of bony edges, are sometimes good markers but they might not be consistently usable. The second step consists of selecting the appropriate size of humeral implant and positioning it. The implant height can be adjusted using information derived from recent work on the pectoralis major.

ANATOMICAL POSITION AND FUNCTIONAL RESULTS

Functional results with hemiarthroplasty in complex four-part fractures are correlated with the height and position of the implant and the anatomical bone union of the tuberosities (5-7). If the position of the humeral stem is correct, the tuberosities will also be at a correct height. In the SOFCOT series of 175 fractures, there was a positioning error in 64% of cases. In a group of 66 patients, Boileau found 50% tuberosity malpositioning and showed a correlation between excessive implant length and tuberosity malpositioning (5). More recently, in a retrospective multicenter analysis of 102 patients, Reuther found a 66% rate of tuberosity nonunion; women had an 11 times higher risk of nonunion (6). Kralinger noted in a group of 167 fractures treated with five types of prostheses, a rate of tuberosity nonunion between 6% and 56%. In addition to nonunion, there was also a tuberosity malunion (bone union with a height discrepancy greater than 5 mm) in 8% to 30% of cases. With four types of prostheses, the tuberosities had healed with less than 5 mm displacement in less than half the cases (7). Therefore, tuberosity fixation is primarily linked to height adjustment in the implant.

LANDMARKS FOR CORRECT HEIGHT POSITIONING

Various techniques have been described to determine precise humeral length. The distance between the upper pole of the stem and the upper edge of the greater tuberosity must be equal to 5 mm. But it is difficult to check this value during surgery because the tuberosities align themselves after the stem is fixed. Dines described a test where the implant is reduced and then inferior traction is applied to sublucate the humeral head; not more than a quarter or at the maximum, half of the glenoid should be visible (8). Likewise, other authors have emphasized the importance of having a maximum of 50% forwards and backwards translation of the test humeral implant on the glenoid (9,10). These intraoperative tests should be looked at, but they bring up several problems: good stability in the test implant is required or an adjustable fixation in the actual implant, and then without fixing the tuberosities, what does this type of displacement mean? Flatow (10), Compito (11) and Boileau (5) described a reconstruction method based on the medial calcar markers, but it would be difficult to apply in cases of severe comminution. Boileau also suggested the use of an external support during planning with the contralateral humerus that has been shown to be capable of copying, but is not used frequently by other teams as it is rather heavy to fit without removing a degree of uncertainty (12). Others have suggested hemiarthroplasty procedures where the height adjustment can be modified with a temporary fixation during the surgery. Thomazeau and the GUEPAR group used the ULYS® implant with an intramedullary alignment system (13). The HUMELock™ implant (FX Solutions, France) is designed with an automatically stem locking (14). Thus after the initial disappointing results caused by a lack of height markers, especially in hemiarthroplasty for fracture, anatomical studies on the tuberosities seem to be necessary. Use of the distance from the apex of the humeral head to the upper edge of the pectoralis major seems to have become the most-trusted measurement. Even though this distance is an interesting point for surgeons now, it is difficult to find a published anatomical description of this distance. Ollier (15) seems to have been the first to describe this distance on a cadaver. On a man of "above average" height, he measured the humerus to be 365 mm long with an apex-pectoralis major distance of 65 mm. In a cadaver study, Gerber created a three-dimensional digital model that was used to calculate the distance between the upper part of the pectoral tendon and the apex of the humeral head; the resulting measurement was 5.19 cm (17). In three cadaver studies (16,18,19), the pectoralis major -apex distance was found to be 5.5 cm ± 0.5 cm, which was smaller than in our study (6.7 cm) (see box below).

ANATOMICAL RESEARCH

Study	No. of cadavers No. of shouders	M/F	Age/Height	Distance
Murachowsky (16)	N=20 cadavers / 40 shouders	11M, 9F	1.62m (range 1.45-1.78)	5.6cm (5.0-7.0cm; SD 0.5cm)
Torrens (18)	N=20 cadavers / 40 shouders CT scan	12M, 8F	68 years old (range 54-96) height NR	5.64cm (5.29-5.99)
Hasan (19)	N=31 cadavers / 38 shouders Distance between Head of humerus and pectoralis major (HP) divided by lenght of humerus (PL)	?	NR	HP=0.2323xPL
Greiner (22)	Clinical study N=30 Comparison between two pros- thesis groups with or without pectoralis major as a landmark		73 years old	5.1 to 5.4cm
Rouchy (21)	Clinical study N=9 where distance used	3 Male, 6 Female	1.68m (range 1.55-1.78) Men: 1.76 Women: 1.64	5.46cm (range 5-6)
Lascar (23)	N=11 cadavers / 11 shouders Clinical study Comparison between two pros- thesis groups with or without pectoralis major as a landmark	?	NR	5.5cm (range 5-6)
Peyron OTSR S 13	N=137 / 200CT scan	112 Male, 88 Female	49.8 years old (range 15-93)	6.7cm Male:7cm Women:6.3cm

Table 1: Pectoralis major used as a landmark

This difference can be explained by the limited number of samples (none having more than 40) and the greater number of men in our study. Our study in fact showed a significant difference in this distance depending on the gender of the subject ($p < 0.001$). It was significantly greater by 7.8 mm in men (20). In the Murachowsky study (16), the average distance was 5.6 cm (range 5-7 cm; SD 0.5 cm), 36/40 shoulders were between 5.0 and 6.0 cm, but in three cases (six shoulders) the distance was equal to or greater than 6 cm, all of them in men over 1.68 m tall. Only four cases (eight shoulders) had an identical measurement to the distance between the sides of a similar cadaver. The Torrens CT scan measurement study (18) on cadavers found a distance of 5.64 cm (range 5.29-5.99); more importantly, this distance was 17.55% (range 16.70-18.39) of the total length of the humerus. Use of this distance as a marker would lead to an error of less than 1 cm in 85% of cases. In the Hasan cadaver study (19) carried out on 31 shoulders (38 cadavers), two measurements were correlated: the apex-pectoralis major (HP) distance and the pectoralis major/lateral epicondyle (PL) distance. HP was measured at 5.77 cm (SD 0.61 cm). However the HP distance was greater than 6 cm in 11 shoulders (eight different cadavers) and less than 5 cm in two shoulders. It was shown that a constant relationship exists between the two measured distances and that is a function of the unique anatomy of each patient. The formula for this relationship is simple and easy to use pre-operatively. The distance of the lateral epicondyle at the upper edge of the insertion can be measured and the formula ($PHP = 0.2323 \times PL$) used to estimate the apex-pectoralis major distance. The average prediction error of 4.11 mm is quite acceptable. Hasan notes that humeral lengthening of five mm and shortening of 1 cm are well tolerated (19).

CLINICAL SERIES

Rouchy (21) reported a short clinical study where a hemiarthroplasty was positioned using these land-marks and the length of the operated humerus was then compared to the healthy humerus: there was a maximum difference of 3%. Greiner (22) showed that in 21/30 patients operated on using the apex- pectoralis major distance (measured between 5.2 and 5.4 cm) to position the hemiarthroplasty, the Constant score was 15 points higher and the DASH score was 20 points higher than when these landmarks were not used. However, this measurement can only be taken by the deltopectoral approach. When using the superior approach and an image intensifier, a new parameter (distance between the pectoralis major and the change in curvature of nearly 3 cm), helps to avoid basic errors and offers yet another way to check if the prosthesis is correctly positioned. No matter which route is chosen, a simple height marker can be retained to avoid errors. The prosthetic head should be placed 6 cm from the upper edge of the pectoralis major and 3 cm from the lateral change in neck curvature, if this has not been damaged by the fracture and is visible on the image intensifier. The advantage of an implant such as the HUMELOCK™ (which can be locked) is that it enables the prosthetic stem to be fixed at an optimal length with a specific tool (14,23) (Figure 2).

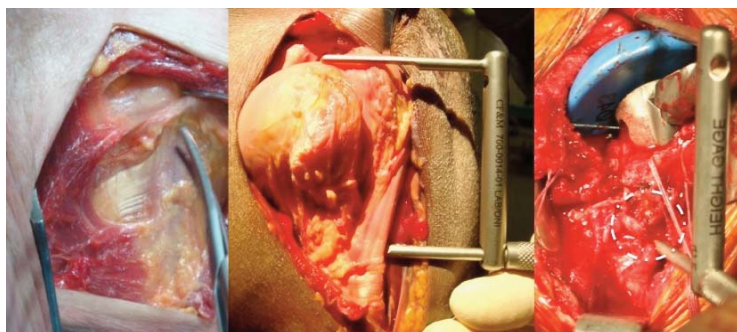


Figure 2: Examples (left shoulder) of the apex of the humeral head to upper edge of the pectoralis major distance. Left image: the upper edge of the pectoralis major is easy to locate on this anatomical dissection. Middle image: specific measurement tool (arbitrarily set at 5.5 cm) used to measure the distance between the apex of the humeral head and upper edge of the pectoralis major. Right image: intraoperative view of the implant being positioned at the correct distance from the upper edge of the pectoralis major (circled in white).

With no cement, an intraoperative correction enables the stem to be adjusted, as necessary, to the height landmarks, which are checked visually and with the image intensifier.

HOW TO FIX WITH SUTURES

This fracture is the only one to be fixed via transosseous sutures. Ideally, a looped suture may be better than a simple suture. The benefit of a loop is two fold. Since this is a tendinous surgical procedure, the quantity of suture is known to confer strength. But the loop suture, used in flexor tendon surgery, allows a simple and efficient running bowline to be performed, with reliable anchoring of the tuberosities. Three sets of two loops appear to be needed: one to anchor and pull traction on the tuberosities, one to maintain the tuberosities on the implant, and the last to act as a vertical support system (Figure 3).

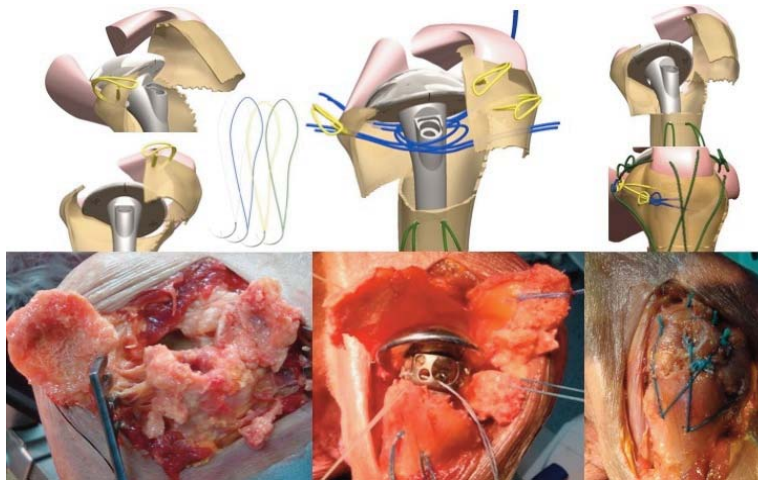


Figure 3: Transosseous suture fixation consisting of three sets of two loops: one to anchor and pull traction on the tuberosities, one to maintain the tuberosities on the implant, and the last to act as a vertical support system.

In addition, the stem design at the metaphysis could reduce primary stability as the tuberosities might slide and capsize under the suture tension. The presence of a sagittal wing may prompt the surgeon to position a tuberosity on either side, but fixation solely at the wing is not sufficient and that wing may constitute a real intratubercular barrier to consolidation. One idea would be to have a metaphyseal device that prevents the medial capsizing effect but allows a graft to be added. The HUMELock™ stem with a metaphyseal cage is one possible solution (Figures 4 & 5).

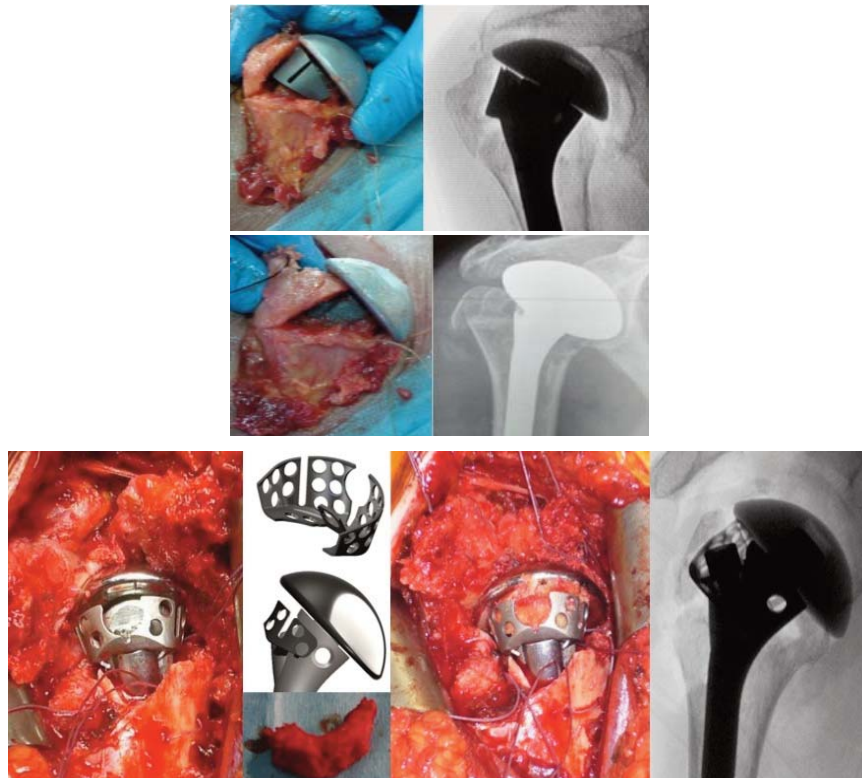


Figure 4: The principle of using a cage to enhance the stability and avoid medialisation of the tuberosities (Offset Modular System®, OMS®, FX Solutions, France).

Figure 5: The second advantage of the Offset Modular System® is that autograft can be added into the metaphyseal cage.

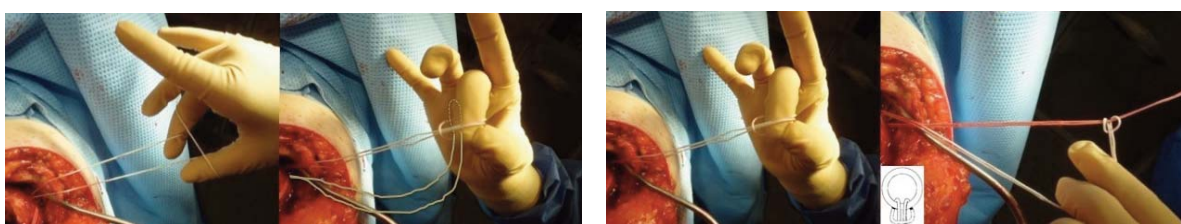


Figure 6: Double ring or tag knot also called double running knot.

THE SERIES (23) (FIGURES 6 TO 9)

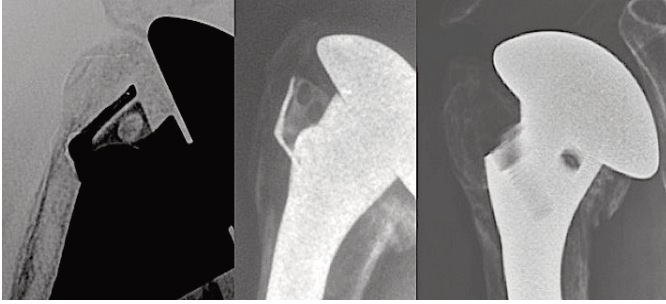


Figure 8: X-rays and CT scan showing union of the tuberosities.

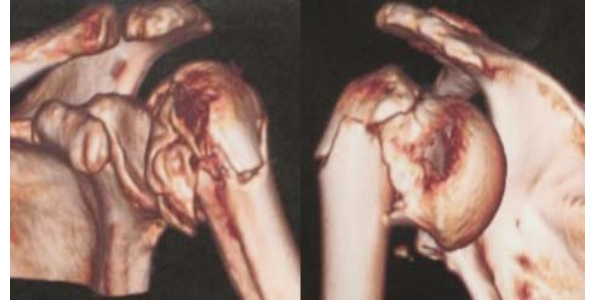


Figure 7: Four-part fracture with dislocation in a 64 year old female (CT4 fracture according to the Duparc classification).



Figure 9: Functional results at six months.

Anatomical work on 14 cadavers and a prospective, clinical multicenter study of 37 cases were conducted to validate the extrapolation of the original solution to the patient. This consisted placing the stem at a height indicated relative to the insertion of the clavicular bundle of the pectoralis major, locking of the stem, placing (based on bone quality) a variable volume metaphyseal cage (Offset Modular System®, OMS®, FX Solutions, France) to avoid medialisation of the tuberosities, and fixing the tuberosities with strong looped sutures (Smartloop® sutures from FX Solutions, which are double ring or tag knots also called double running knots (figure 6)). Evaluation of Constant score, Quick DASH, bone union of tuberosities at 6 months (X ray & CT scan) was done by a surgeon not involved in the treatment. The distal double-locking instrument and the suturing technique for the tuberosities using looped sutures were judged to be effective by all the involved surgeons. The clinical study enabled the apex-pectoralis major tendon distance of $5.5 \text{ cm} \pm 0.5 \text{ cm}$ to be determined, which confirmed the results of the anatomical study and was consistent with published data. Three senior surgeons operated on 23/37 patients (three males; 18 four-part fractures) with a mean age of 64.6 years (range 49-85). They were reviewed with a mean follow-up of 17.3 months (range 6-24). All patients were seen again at three and six months. At the follow-up, the average maximum abduction was 94.7° (range 45-130), active anterior elevation was 113.25° (range 160-60), and external rotation was 29° (range 0-45). One complication was noted: inadequate position of a locking screw. In the 17 patients operated without the OMS®, the initial positioning of the tuberosities was adequate in 50% of cases and secondary displacement occurred in 10% of cases. In the six patients operated with the OMS®, 100% had adequate initial positioning of the tuberosities and no secondary displacement was observed. The Quick DASH reached 32.4/100 (15-55) and the weighted Constant score was 76 (64-94).

CONCLUSION

The durability of tuberosity fixation around a humeral fracture implant mostly depends on the height of the stem: reproducible stem positioning can be achieved with a landmark at the pectoralis major tendon (24). Transosseous suture fixation is an indispensable tool for anchoring the tuberosities (24). However, the metaphysis shape of the implant, available bone stock and construct stability all contribute to stable and long-lasting fixation. Even if tuberosity fixation remains a challenge in hemiarthroplasty for fracture, the technical principles are now well-known. Now we have to convince our colleagues that tuberosity fixation during reverse shoulder arthroplasty is needed to achieve good functional results in elderly but active patients (25,26). The search for optimal fixation must continue and the best educational methods for this demanding technique must be explored.

REFERENCES

- 1/ Boons HW, Goosen JH, van Grinsven S, van Susante JL, van Loon CJ. Hemiarthroplasty for Humeral Four-part Fractures for Patients 65 Years and Older: A Randomized Controlled Trial. Clin Orthop Relat Res. 2012 (in press)
- 2/ Clavert P, Adam P, Bevort A, Bonnomet F, Kempf JF. Pitfalls and complications with locking plate for proximal humerus fracture. J Shoulder Elbow Surg. 2010; 19:489-94.
- 3/ Schliemann B, Siemoneit J, Theisen Ch, Kösters C, Weimann A, Raschke MJ. Complex fractures of the proximal humerus in the elderly. outcome and complications after locking plate fixation. Musculoskelet Surg. 2012 ;96 :S3-11.
- 4/ Cai M, Tao K, Yang C, Li S. Internal fixation versus shoulder hemiarthroplasty for displaced 4-part proximal humeral fractures in elderly patients Healio.com/Orthopedics 2012 ; 35 : e1340-1346
- 5/ Boileau P, Krishnan SG, Tinsi L, Walch G, Coste JS, Molé D. Tuberosity malposition and migration: reasons for poor outcomes after hemiarthroplasty for displaced fractures of the proximal humerus. J Shoulder Elbow Surg. 2002; 11:401-12.
- 6/ Reuther F, Mühlhäusler B, Wahl D, Nijs S. Functional outcome of shoulder hemiarthroplasty for fractures: A multicentre analysis. Injury 2010 ; 41: 606-12
- 7/ Kralinger F, Schwaiger R, Wambacher M, Farrell E, Menth-Chiari W, Lajtai G, Hübner C, Resch H. Outcome after primary hemiarthroplasty for fracture of the head of the humerus. A retrospective multicentre study of 167 patients. J Bone Joint Surg . 2004; 86B: 217-9.
- 8/ Dines DM, Warren RF. Modular shoulder hemiarthroplasty for acute fractures. Surgical considerations. Clin Orthop Relat Res. 1994; 307:18-26.
- 9/ Mighell MA, Kolm GP, Collinge CA, Frankle MA. Outcomes of hemiarthroplasty for fractures of the proximal humerus. J Shoulder Elbow Surg. 2003; 12: 569-77.
- 10/ Flatow E. Technique of prosthetic replacement for proximal humeral fractures. Techniques in Orthopaedics. 1994; 9: 154-59.
- 11/ Compito CA, Self EB, Bigliani LU. Arthroplasty and acute shoulder trauma. Reasons for success and failure. Clin Orthop Relat Res. 1994; (307):27-36.
- 12/ Boileau P, Walch G. Shoulder arthroplasty for fractures: problems and solutions. In: Walch G, Boileau P, eds. Shoulder Arthroplasty. Springer-Verlag; 1999:297-314.
- 13/ Thomazeau H, Ropars M, et le GUEPAR Prothèses humérales pour fractures In: Fontaine C, Masméjean E (ed). Prothèses articulaires du membre supérieur Monographie Cours Européen HEGP, Sauramps Médical 2009: 39-44
- 14/ Lascar T, Daudet JM, Heraud D, Martin JJ, Obert L. Comment améliorer la fixation des tubérosités dans les fractures céphalo tubérositaires In: Dubrana F, Gunepin FX D(ed). Trucs et Astuces Tome 6, Sauramps Médical 2010: 17-22
- 15/ Ollier L. Résection de l'épaule In : Traité des résections et des opérations conservatrices qu'on peut pratiquer sur le système osseux Tome 2. Masson 1888: 82
- 16/ Murachovsky J, Ikemoto RY, Nascimento LG, Fujiki EN, Milani C, Warner JJ. Pectoralis major tendon reference (PMT): a new method for accurate restoration of humeral length with hemiarthroplasty for fracture. J Shoulder Elbow Surg. 2006 ;15:675-8.
- 17/ Gerber A, Apreleva M, Harrold F, Warner JJP. The value of the pectoralis major tendon as an anatomic landmark to determine humeral length and retroversion. Poster presented at The 8th International Congress of Shoulder and Elbow Surgery (ICSES) 2001; Capetown .
- 18/ Torrens C, Corrales M, Melendo E, Solano A, Rodríguez-Baeza A, Cáceres E. The pectoralis major tendon as a reference for restoring humeral length and retroversion with hemiarthroplasty for fracture. J Shoulder Elbow Surg. 2008 ;17:947-50.
- 19/ Hasan SA, Rauls RB, Cordell CL, Heinzelmann AD, Siegel ER. Pectoralis major insertional ratio in proximal humerus fractures: a method to reconstruct humeral head height in arthroplasty. Orthopedics. 2009;32 : (10). orthosupersite.com
- 20/ Obert L, Peyron C, Uhring J, Jardin E, Rochet S, Lascar T, Aubry S. Analysis by 137 CT scan of the distance humeral head apex/ pectoralis major. Orthop Traumatol Surg Res 2013 (accepted)
- 21/ Rouchy RC, Belvisi B, Roudet A, Chirpaz-Cerbat JM. Restauration de la longueur humérale lors des arthroplasties d'épaule pour fracture : utilisation du tendon du grand pectoral comme repère In: Dubrana F, Gunepin FX D(ed). Trucs et Astuces Tome 6, Montpellier Sauramps Médical 2010: 35-41
- 22/ Greiner SH, Käb MJ, Kröning I, Scheibel M, Perka C, Reconstruction of humeral length and centering of the prosthetic head in hemiarthroplasty for proximal humeral fractures. J Shoulder Elbow Surg. 2008; 17:709-714.
- 23/ Lascar T, Rochet S, Vidil A, Hery JY, Juvenspan M, Bellumore Y, Peyroux M, Fisher JF, Obert L. Dedicated anatomic prostheses for proximal humerus fracture. Technical solutions to improve tuberosity consolidation, with radiological and clinical analysis of results. Orthop Traumatol Surg Res 2012 ; 98S : S68-S72
- 24/ Sirveaux F, Roche O, Molé D. Shoulder arthroplasty for acute proximal humerus fracture. Orthop Traumatol Surg Res. 2010 ;96:683-94
- 25/ Gallinet D, Clappaz P, Garbuio P, Tropet Y, Obert L. Three or four parts complex proximal humerus fractures: Hemiarthroplasty versus reverse prosthesis: A comparative study of 40 cases. Orthop Traumatol Surg Res 2009; 95; 48-55
- 26/ Gallinet D, Adam A, Gasse N, Rochet S, Obert L. Improvement in shoulder rotation in complex shoulder fractures treated by reverse shoulder arthroplasty. J Shoulder Elbow Surg 2012 (in press)

